



## Case Report

# Pericapsular nerve group (PENG) block as a sole anesthetic method for malignant soft tissue excision

Ela Nur Medetoglu<sup>a,\*</sup> , Veysel Koksall<sup>a</sup> , Mehmet Akif Yilmaz<sup>a</sup> , Elif Oral Ahiskalioglu<sup>a</sup> 

<sup>a</sup> Department of Anesthesiology and Reanimation, Atatürk University, Faculty of Medicine, Erzurum, Türkiye

## ABSTRACT

Since its first description by Philippe WH Peng in 2018, the Pericapsular Nerve Group (PENG) block, a novel regional anesthetic procedure, has been gaining in popularity. In order to provide appropriate analgesia, an ultrasound-guided local anesthetic injection around the hip joint is performed.

We presented, in this case, the successful management of the PENG block for surgical anesthesia in the excision of a malignant soft tissue tumor in the proximal tibia of a 73-year-old female patient. Adequate sensory and motor blocks were obtained, allowing a 70-minute surgery without using additional analgesics. Postoperative pain scores were low, and the patient was discharged without complications.

## ARTICLE INFO

### Article history:

Received 4 April 2023

Revised 30 April 2023

Accepted 25 May 2023

### Keywords:

Pericapsular nerve group block

Surgical anesthesia

High risk patient

## 1. Introduction

Pericapsular Nerve Group (PENG) block is a relatively novel regional anesthesia technique that has gained increasing popularity in recent years. The PENG block is an injection that is given peri-capsularly around the hip joint under ultrasound guidance. It was first described in 2018 for analgesia after hip fractures [1]. The anterior inferior iliac bone and iliopubic eminence are used as the anatomical landmark. Local anesthetic is injected under and into the fascial layers that separate the iliopsoas muscle from the bone surface. The hip joint capsule is innervated by the femoral nerve and also several smaller nerves as the articular branches of the femoral, the articular branches of the obturator and the accessory obturator nerve that supply the anterior capsule. The quadratus femoris nerve supplies the posterior capsule.

In this case, we present the application of PENG block for successful surgical anesthesia in the excision of malignant soft tissue in the proximal tibia. Written consent was obtained from the patient for the publication of the article.

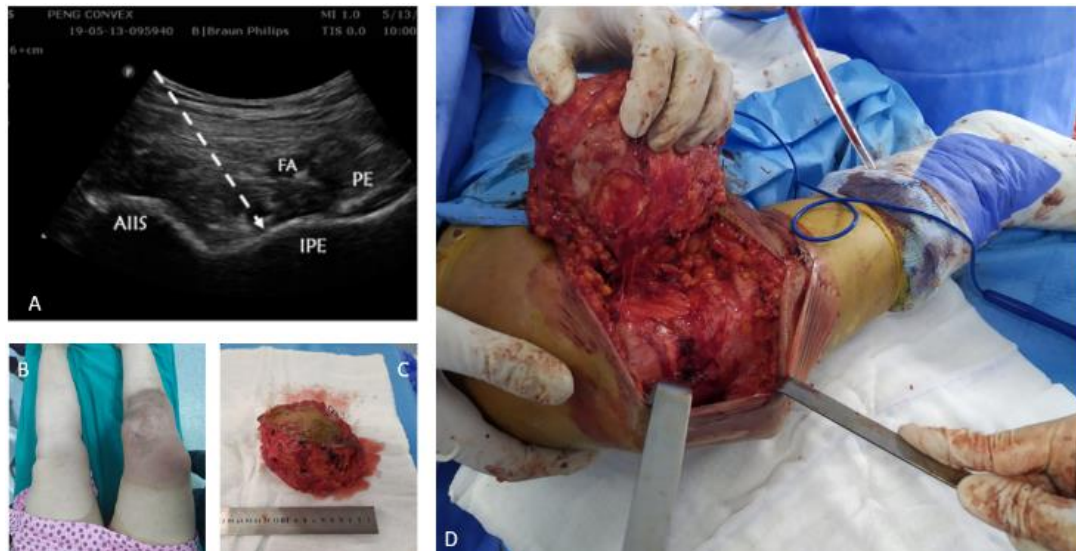
## 2. Case Report

A 73-year-old 80 kg female patient with ASA-III, a medical history of coronary artery disease, hypertension and atrial fibrillation had a mass measuring 15x11x7.6 cm in the medial right proximal tibia. Mass excision was planned for the patient. Due to the location of the lesion and comorbidities, we decided to perform PENG block for surgical anesthesia. Standard monitoring was performed on the patient in the operating room. The US probe (Xperius®, B Braun-Philips, C5-2 broadband curved array transducer, Melsungen, Germany) was covered with a sheath under aseptic conditions. After the anterior inferior iliac spine was palpated, a convex probe was placed transversely on it. The probe was then rotated 45 degrees to visualize the pubic ramus. The pectineus, iliopsoas muscle, and femoral artery were visualized. After 2 ml saline injection to confirm the correct spreading then, a 100mm ultrasound visible needle (Stimuplex® Ultra 360®, B Braun, Melsungen, Germany) was inserted lateral to medial and 30 ml of local anesthetic (15 ml 2% lidocaine, 15 ml 0.5% bupivacaine) was injected between the psoas tendon and the pubis ramus. After approximately 20

\* Corresponding author. Tel.: +90-442-344-8796 ; Fax: +90-442-236-1301 ; E-mail address: elamdtoğlu@gmail.com (E. N. Medetoglu)

minutes, sensory tests (cold test) of the femoral nerve, obturator nerve, and lateral femoral cutaneous nerve dermatomes provided adequate anesthesia. Motor block also occurred in the patient. Motor block tested with quadriceps weakness of the thigh. The surgical procedure was started 30 minutes after the block procedure. A total of 1 mg of midazolam and 40 mg of propofol were administered for sedation throughout

the surgery. The operation lasted 70 minutes. During the operation, the patient did not need additional analgesics. IV paracetamol was administered every 6 hours postoperatively. The VAS score was recorded as 0 during the first 6 hours in the postoperative follow-up. In the first 24 hours, the highest visual analog score (VAS) was 3. The patient was discharged the next day without any problem (Fig. 1).



**Fig. 1.** (a) Sonographic anatomy. AIIS: anterior inferior iliac spine, FA: Femoral artery, PE: pectineus muscle, IPE: iliopubic eminence; (b) Surgical areas of patient; (c) Excisional mass; (d) Surgical area and a mass in the proximal medial tibia.

### 3. Discussion

The use of regional anesthesia techniques, including peripheral nerve blocks, has been increasing in popularity in recent years due to their potential benefits in terms of pain management and reducing the need for opioids. The application of PENG block for surgical anesthesia in the excision of malignant soft tissue in the proximal tibia, as described in this case report, highlights the potential versatility and efficacy of this relatively new regional anesthesia technique. Successful utilization of the PENG block for surgical anesthesia in this case suggests that it may be a viable alternative to more traditional anesthesia techniques, particularly for patients with medical comorbidities or those at high risk for complications from general anesthesia. Adopting Enhanced Recovery After Surgery (ERAS) protocols has yielded favorable outcomes such as shortened hospital stays, decreased incidence of complications, and reduced costs. Additionally, using the PENG block has facilitated earlier ambulation and opportunities for physiotherapy, resulting in reduced motor deficits and improved patient satisfaction [2].

Recent studies have shown that PENG block performed at high volumes will also reach the lateral and block the lateral femoral cutaneous nerve. Studies are stating that it can have the same effect as the lumbar plexus block. This extends the indications for the PENG block to the more distal parts of the lower extremity. Studies have shown that successful results are obtained

in mass excisions in the medial thigh, varicose surgery, and fixation of ankle fractures [3–5]. Local anesthetic dissemination has been demonstrated by cadaveric studies [6,7]. These findings support the notion that PENG block has the potential for broader application, beyond its initial description for hip fracture analgesia. A meta-analysis of five randomized controlled trials showed that PENG block positively affected pain scores by reducing opioid consumption after hip surgery [8]. Despite certain limitations regarding using this block in pediatric patients, a study has reported the safe implementation of PENG block in two children undergoing surgery for hip dysplasia [9].

In addition to providing preoperative analgesia, PENG block can offer effective surgical anesthesia in appropriate dermatomal regions. As a result of the fact that this method is still relatively new, there is ongoing discussion on the optimal injection point, the optimal anesthetic concentration, and the total volume that should be injected. The scope and application of the PENG block can be expanded proportionately to the concentration and volume of the administered local anesthetic, thereby broadening its potential indications and areas of use. Nonetheless, additional randomized clinical trials and cadaveric and radiographic studies are necessary to determine the efficacy of PENG block. Additionally, comparisons with existing regional anesthesia techniques would provide valuable information regarding the relative advantages and disadvantages of PENG block in various clinical contexts.

## Acknowledgements

None declared.

## Funding

The authors received no financial support for the research, authorship, and/or publication of this manuscript.

## Conflict of Interest

The authors declared no potential conflicts of interest with respect to the research, authorship, and/or publication of this manuscript.

## REFERENCES

1. Girón-Arango L, Peng PWH, Chin KJ, Brull R, Perlas A. Pericapsular Nerve Group (PENG) Block for Hip Fracture. *Reg Anesth Pain Med* **2018**; 43:859-863.
2. Picart B, Lecoœur B, Rochcongar G, Dunet J, Pégéox M, Hulet C. Implementation and results of an enhanced recovery (fast-track) program in total knee replacement patients at a French university hospital. *Orthop Traumatol Surg Res* **2021**; 107:102851.
3. Aydin ME, Borulu F, Ates I, Kara S, Ahiskalioglu A. A Novel Indication of Pericapsular Nerve Group (PENG) Block: Surgical Anesthesia for Vein Ligation and Stripping. *J Cardiothorac Vasc Anesth* **2020**; 34:843-845.
4. Ahiskalioglu A, Aydin ME, Celik M, Ahiskalioglu EO, Tulgar S. Can high volume pericapsular nerve group (PENG) block act as a lumbar plexus block? *J Clin Anesth* **2020**; 61:109650.
5. Ahiskalioglu A, Aydin ME, Ahiskalioglu EO, Tuncer K, Celik M. Pericapsular nerve group (PENG) block for surgical anesthesia of medial thigh. *J Clin Anesth* **2020**; 59:42-43.
6. Ciftci B, Ahiskalioglu A, Altintas HM, Tekin B, Sakul BU, Alici HA. A possible mechanism of motor blockade of high volume pericapsular nerve group (PENG) block: A cadaveric study. *J Clin Anesth* **2021**; 74:110407.
7. Yamak Altinpulluk E, Galluccio F, Salazar C et al. Peng block in prosthetic hip replacement: A cadaveric radiological evaluation. *J Clin Anesth* **2020**; 65:109888.
8. Wang Y, Wen H, Wang M, Lu M. The Efficiency of Ultrasound-Guided Pericapsular Nerve Group Block for Pain Management after Hip Surgery: A Meta-analysis. *Pain Ther* **2023**; 12:81-92.
9. Domagalska M, Wieczorowska-Tobis K, Reysner T, Geisler-Wojciechowska A, Grochowicka M, Kowalski G. Pericapsular Nerves Group (PENG) Block in Children under Five Years of Age for Analgesia in Surgery for Hip Dysplasia: Case Report. *J Pers Med* **2023**; 13.