





Case Report

Perioperative ventricular dysrhythmia management in ranula cyst excision surgery

Merve Yaman ^{a,*} , Tayfun Aydın ^b , Osman Pala ^c 

^a Department of Anesthesiology and Reanimation, Kütahya Evliya Çelebi Research Hospital, Kütahya, Türkiye

^b Department of Anesthesiology and Reanimation, Kütahya University of Health Sciences, Kütahya, Türkiye

^c Department of Otorhinolaryngology, Kütahya Evliya Çelebi Research Hospital, Kütahya, Türkiye

ABSTRACT

Ranula cyst is one of the most common pathologies of the sublingual salivary gland. It is formed as a result of damage to the gland ducts and is a retention cyst filled with mucus. Methods such as drainage, excision or cryosurgery are used in the treatment. During surgical treatment, it may cause various dysrhythmias due to its anatomical relationship with the vagus nerve. In this study, we aimed to present our response to arrhythmias seen during ranula cyst excision and resistant to IV administration with local lidocaine administration.

ARTICLE INFO

Article history:

Received 16 April 2024

Revised 24 May 2024

Accepted 7 June 2024

Keywords:

Lidocaine

Ventricular arrhythmia

Ranula

Vagus



This is an open access article distributed under the CC BY licence.

© 2024 by the Authors.

1. Introduction

The sublingual glands are the smallest of the major salivary glands. The most common pathology is the ranula [1]. A ranula cyst is a mucus-filled retention cyst formed due to damage to the ducts of the sublingual salivary gland, located at the anterior part of the floor of the mouth. It can extend from the base of the skull to the mediastinum [2]. Clinically, it can be sublingual or sublingual plunging (cervical). Those that reach the cervical region by passing the mylohyoid muscle are called plunging ranula, and cases where oral and cervical ranula co-exist are called sublingual plunging ranula. The most common type is sublingual ranula. Treatment methods include drainage, excision, and cryosurgery [2,3].

Lidocaine is a medium-duration and fast-onset amide group local anesthetic. In addition to its local anesthetic effect, lidocaine is a Class IB antiarrhythmic that signifi-

cantly shortens the action potential duration in Purkinje fibers and ventricular myocardium, although it does not alter it in atrial myocardium. It is one of the first-choice drugs in treating ventricular tachyarrhythmias [4]. It is also known that lidocaine, when administered intravenously during surgery, can effectively block sodium channels in the myocardium against ischemia-reperfusion injury [5].

Although ranula cysts are mostly simple mucus-filled cysts, their surgical treatment poses risks, such as the involvement of the vagus nerve. The nervus vagus is the longest cranial nerve. After exiting the jugular foramen, it travels between the internal carotid artery and the internal jugular vein in the neck, proceeding past the larynx, esophagus, and trachea to reach the gastrointestinal organs. It plays a crucial role in the autonomic control circuit of the central nervous system with the brainstem. The vagus provides a wide range of afferent and efferent

* Corresponding author. E-mail address: drmerveyaman@hotmail.com (M. Yaman)

innervation for the internal organs [6–8]. During its course in the neck, the nervus vagus gives off the superior laryngeal nerve and the cervical cardiac branches, forming the cardiac plexus [9]. It also establishes a close connective tissue relationship with the hypoglossal nerve at its inferior ganglion, where they exchange fibers [10].

In our case report, the patient had a preoperative diagnosis of supraventricular tachycardia (SVT). We think that this situation may be related to surgical manipulation as well as the local effect of the existing ranula cyst. Our aim was to emphasize the response of the patient with ranula cyst to the antiarrhythmic effect of lidocaine applied locally during the operation.

2. Case Report

A 28-year-old male patient with known SVT, who was on metoprolol and had a BMI of 26.23; presented to the otorhinolaryngology clinic with the complaint of slowly growing swelling at the floor of the mouth. As a result of the examination and investigations, he was diagnosed with a sublingual ranula cyst (Fig. 1), and surgery was planned. The patient was evaluated as ASA class II according to the American Society of Anaesthesiologists classification.

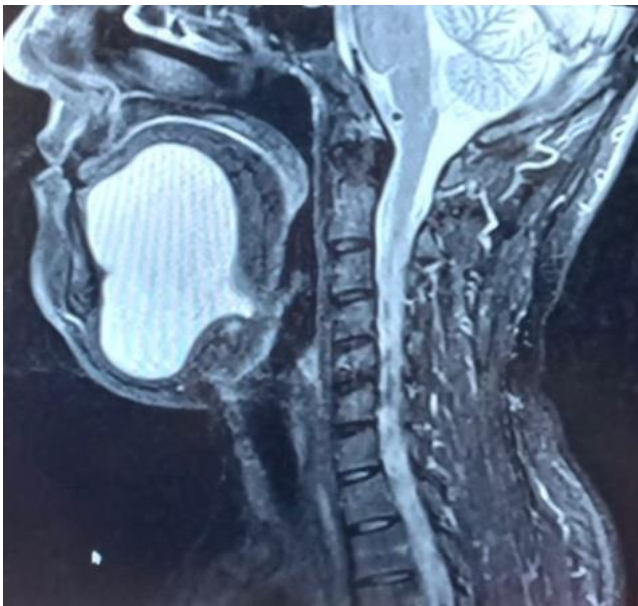


Fig. 1. Radiological image of the ranula cyst.

In the operating room, standard non-invasive monitoring was applied. Blood pressure: 130/60 mmHg, pulse: 95/min, SpO₂: 96% on room air. The patient's vital values were stable, but ventricular extrasystoles (VES) were intermittently observed on the ECG. Following pre-oxygenation, 1 mg/kg of IV lidocaine was administered. Induction was initiated in patient with no dysrhythmia. Propofol 2 mg/kg, fentanyl 1.5 mg/kg, and rocuronium bromide 0.6 mg/kg were administered intravenously. Nasal intubation was performed. For anesthesia maintenance, sevoflurane and remifentanyl infusion at 0.6

mcg/kg/min were added. During surgery (Fig. 2), recurrent VES episodes were noted, leading to three additional IV lidocaine administrations.

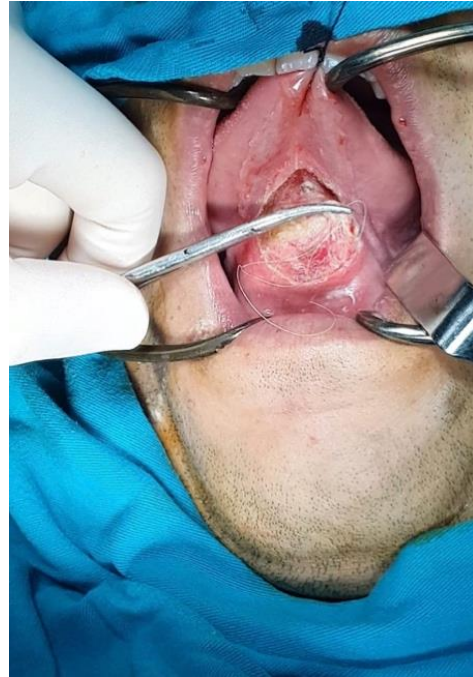

Fig. 2. Surgical area.

During the dissection of the ranula cyst, as dysrhythmias increased. Then the surgical team requested the local administration of lidocaine at a dosage of 1 mg/kg. Dissection continued after a few minutes of waiting (Fig. 3). No further VES episodes were observed for the remainder of the operation, which lasted about an hour. The patient was extubated after administering analgesics and antiemetics. No dysrhythmia episodes were observed in the first 24 hours postoperatively. The patient was referred to the cardiology clinic for VES management.

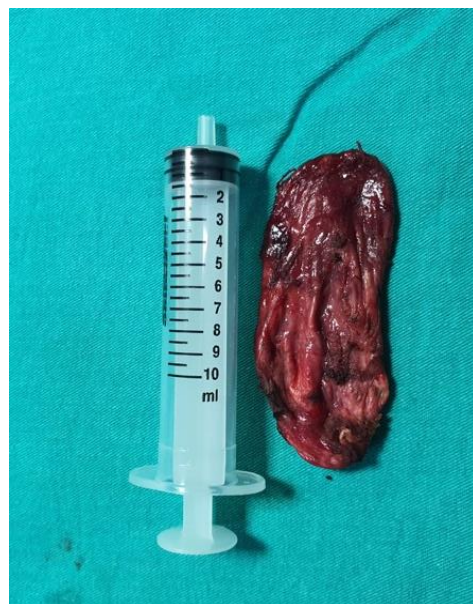

Fig. 3. Excised mass.

3. Discussion

The nervus vagus is the longest cranial nerve. Its anatomy and physiology are complex. It affects numerous organ systems of the body, such as the heart, tongue, pharynx and gastrointestinal tract [6]. Literature shows that intraoperative manipulation of the vagal nerve can cause cardiac and circulatory fluctuations in patients, resulting in dysrhythmias and low blood pressure. Additionally, involvement of the inferior laryngeal nerve, a branch of the vagus, can lead to symptoms such as hoarseness, dysphagia, airway obstruction, and dyspnea [11–13].

The parapharyngeal space at the base of the skull is bounded by the ramus of the mandible, parotid gland, vertebral column, and parapharyngeal wall. This space contains cranial nerves IX, X, XI, and XII, along with cervical sympathetic nerves, major blood vessels, lymph nodes, and chemoreceptive tissues [12]. Therefore, surgical procedures in this area may damage these structures.

Ranula cysts are mostly simple mucus-filled cysts and the nervus vagus may be affected in surgical treatment. Dangerous sudden dysrhythmias (VES, bradycardia, etc.) may occur during removal of tissues such as ranula cysts. Therefore, careful monitoring and cooperation between the anaesthetist and the surgeon is essential. Our literature review revealed publications indicating the occurrence of perioperative dysrhythmias during the excision of masses such as schwannomas but lacking guidelines on treatment approaches when encountering such situations.

Ye et al. [11] reported marked intraoperative dysrhythmia during cervical vagal nerve schwannoma excision, which was resistant to IV lidocaine. They suggested that the damage to the cervical vagus nerve during schwannoma excision might interfere with heart rate control, leading to dysrhythmias. In our case, the hypoglossal and lingual nerves were seen and manipulated during the excision. Anatomically, these nerves are closely related to the course of the vagus nerve in the neck [10]. We believe this close relationship contributed to the dysrhythmia observed in our case.

4. Conclusions

In our case, we demonstrated that the antiarrhythmic effect of lidocaine can also be achieved through local application. Additionally, we believe that the experience of the anesthesia team and the multidisciplinary approach with the surgical team can reduce the frequency of potential complications. Finally, we think it is important for clinicians to be alert to the potential development of ventricular dysrhythmia during ranula cyst excision. We also emphasize that they should consider alternative treatment modalities to effectively manage this condition.

Acknowledgements

None declared.

Funding

The authors received no financial support for the research, authorship, and/or publication of this manuscript.

Conflict of Interest

The authors declared no potential conflicts of interest with respect to the research, authorship, and/or publication of this manuscript.

Author Contributions

All of the authors made substantial contributions to conception and design, or acquisition of data, or analysis and interpretation of data; were involved in drafting the manuscript or revising it critically for important intellectual content; and gave final approval of the version to be published.

Data Availability

The datasets created and/or analyzed during the current study are not publicly available, but are available from the corresponding author upon reasonable request.

Ethics Approval and Consent to Participate

None declared.

REFERENCES

- Gontarz M, Bargiel J, Gašiorowski K, Marecik T, Szczurowski P, Zapala J, et al. Surgical treatment of sublingual gland ranulas. *Int Arch Otorhinolaryngol* **2023**; 27(02):e296–301.
- Çankaya H, Kutluhan A, Kırış M, İçli M. Basit ranula: Olgularımız ve tedavi yaklaşımlarının değerlendirilmesi. *Van Med J* **2001**; 8(4):128–130.
- Yapıcı Yavuz G, Yavuz MS, Koparal M. Sublingual ranula: Case report. *Adiyaman Univ J Health Sci* **2016**; 2(2):287–96.
- Kayaalp O. Medical pharmacology in the direction of rational treatment. *Anti Arrhythmic Drugs* **2002**; 510–51.
- Hearse DJ. Ischemia, reperfusion, and the determinants of tissue injury. *Cardiovasc Drugs Ther* [Internet] **1990**; Suppl 4:767–76.
- Sorgun MH. Anatomy of Cranial Nerves. Anatomy Department, Ankara University, 2011.
- Ergün AC, Kök S, Öztürk S. Vagal nerve stimulation: Surgical technique and complications. *Turk Neurosurg J* **2021**; 31(3):368–373.
- Kenny BJ, Bordoni B. Neuroanatomy, Cranial Nerve 10 (Vagus Nerve); **2023**. <https://www.ncbi.nlm.nih.gov/books/NBK537171/> [accessed 16 November 2023]
- Nur Gökçe E. The secret of a longevity: The vagus nerve. *İstanbul Bilim University Florence Nightingale Journal of Medicine* **2018**; 4(3):154–165.
- Bahşi I. Nervus Hypoglossus; **2023**. <https://www.researchgate.net/publication/328028635> [accessed 16 November 2023]
- Ye P, He C, Chen Y, Wu H, Li Y, Cai C, et al. Cervical vagal nerve schwannoma induced arrhythmia: a rare case report and literature review. *BMC Neurol* **2022**; 22(1).
- Wood BM, Mcneil WT. Schwannoma of the vagus nerve. *Anaesthesia* **1986**; 41(11):1130–1132.
- Hacking C. Pulmonary plexus. In: Radiopaedia.org; **2022**.